United States
Environmental Protection
Agency

Office of
Pesticide Programs

54019873

Toxic Substances

EPA

Classification of Proliferative Hepatic Lesions in Mice



CLASSIFICATION OF PROLIFERATIVE HEPATIC LESIONS IN MICE - AN EPA SPONSORED WORKSHOP[1]

The Steering Committee

Dr. Joseph Burek, Dr. Charles Frith, Dr. F. M. Garner,
Dr. Bernard Haberman, Mr. Steve Johnson, Dr. Sidney Jones,
Dr. Ronald L. Schueler, Dr. Robert A. Squire, Dr. James Stookey,
Ms. Vivian Turner, Dr. Jerrold M. Ward, Dr. Adrienne Zahner

[1]This report has been reviewed by the Office of Pesticides and Toxic Substances, U.S. Environmental Protection Agency, and approved for publication. Approval does not signify that the contents necessarily reflect the views and policies of the U.S Environmental Protection Agency, nor does mention of trade names or commercial products constitute endorsement or recommendation of use.

ABSTRACT

The Environmental Protection Agency (EPA) sponsored a workshop in 1980 to characterize and classify hepatic neoplasms in mice. The principal goal of the workshop was to develop a guideline in the diagnosis and interpretation of hepatic lesions in the mouse commonly observed in oncogenicity tests. Criteria for classification were reached by a consensus of the workshop participants.[2] This nomenclature was proposed to bring consistency in the diagnosis and interpretation of mouse liver neoplasms. Participants agreed that future research findings might alter this terminology as new information on the biological behavior of these neoplasms emerges.

Lesions were classified as follows: (1) Focus of cellular alteration (2) hepatocellular adenoma (3) hepatocellular carcinoma and (4) non-hepatocytic malignant neoplasms of cholangiolar or vascular origin.

Criteria for characterization of lesions were given.

[2]Dr Gary Boorman, Dr. Joseph Burek, Dr. Alex Cameron, Dr. Charles Frith, Dr. F.M. Garner, Dr. Dawn G. Goodman, Dr. Paul Grasso, Dr. Richard A. Griesemer, Dr. Bhola Gupta, Dr. Bernard Haberman, Dr. Jerry Hardisty, Dr. G.H. Hottendorf, Mr. Stephen Johnson, Dr. Sidney Jones, Dr. Shoichi Katayama, Dr. Choudari Kommineni, Dr. Michael Lipsky, Dr. Ernest E. McConnell, Dr. Ronald Moch, Dr. Richard J. Montali, Dr. James A. Popp, Dr. Melvin Reuber, Dr. Boris Reubner, Dr. Gerd Reznik, Dr. Ronald L. Schueler, Dr. Stewart Sell, Dr. Winslow Sheldon, Dr. Robert A. Squire, Dr. Sherman Stinson, Dr. James Stookey, Dr. Glen Todd, Dr. John Toft, Dr. Leander Tryphonas, Dr. Jerrold M. Ward, Dr. Morris A. Weinberger, Dr. Adrienne Zahner, Dr. Chris Zurcher.

INTRODUCTION

The goal of the workshop was to develop a guideline for use by pathologists. Such a guideline would provide a meaningful and logical standard to judge the significance of liver lesions in mice from oncogenicity and toxicity testing. Scientists with extensive experience in pathology and in diagnosis and interpretation of proliferative lesions of the mouse liver participated to develop the guidance.

Studies have shown wide differences of opinion regarding the classification and nature of lesions of the mouse liver. A variety of terms have been employed to describe benign and malignant neoplasms commonly encountered in laboratory mice.

It is well established that the mouse liver is often a target organ in toxicity and oncogenicity testing. Since the results of these tests may serve as the scientific basis for regulatory decisions, a standardized classification and nomenclature for identification of lesions in the mouse liver is essential.

MATERIALS AND EVALUATIONS

Mouse liver sections for microscopic evaluation were selected from the National Center for Toxicological Research and the National Cancer Institute/National Toxicology Program to provide a full spectrum of hepatocellular lesions commonly observed in bioassay testing. Duplicate slide sets were prepared from Bouin's-fixed tissues, stained with hematoxylin and eosin, and distributed to participants in advance of the workshop. Animal histories, including a gross description of liver lesions at necropsy, were submitted with the microslides. Diagnoses and opinions concerning the nature of the lesions were submitted prior to the workshop; the results were tabulated and distributed at the workshop.

Photomicrographs were made of representive microscopic lesions for presentation. At the workshop projected photomicrographs were evaluated.

At the end of two and one-half days of presentation, discussion, review and voting, a consensus was reached regarding diagnosis and interpretation of the proliferative hepatocellular changes that are commonly observed in the mouse liver. Participants defined and established criteria for common occurring lesions, to establish an uniform nomenclature.

CRITERIA AND DISCUSSION

The following criteria for classification of proliferative hepatocellular lesions frequently seen in the mouse liver were arrived at by consensus. Photomicrographs were selected to demonstrate features or criteria agreed to by participants and represent only a portion of the slides actually reviewed by participants.

FOCUS OF CELLULAR ALTERATION: Foci are generally less than a lobule in size, but may occasionally occupy a few lobules. Cytoplasm may be basophilic (Fig. 1), vacuolated (Fig. 2), eosinophilic (Fig.3), or a combination of these cell types. Compression may not be a feature of this lesion. The term preneoplasia should be avoided in connection with foci because their true nature is not well defined.

HEPATOCELLULAR ADENOMA: Adenomas are generally several lobules in size or greater. Compression is prominent or significant. The lobular pattern of architecture is lost and cells are arranged as single or multiple-cell thick trabeculae which may be disoriented and lack continuity with adjacent normal tissue. Hepatocytes are generally uniform in size and shape, well-differentiated, and may be basophilic (Fig. 4), vacuolated (Fig. 5), eosinophilic or combinations of these cell types (Fig. 6). Some pleomorphism may occur (Fig. 7). The degree of trabeculae formation and pleomorphism differentiates adenoma from carcinoma.

Adenomas should not have portal triads associated with a normal lobular pattern, but triads may be entrapped in the lesion.

HEPATOCELLULAR CARCINOMA: General features are similar to adenoma, except that the trabeculae formation is often more prominent and several cells thick, and formation of acinar structures are sometimes observed (Fig. 8). The degree of cellular pleomorphism or atypia is more pronounced than in adenoma (Fig. 9). Transitional varieties consisting of a combination of hepatocytes and cells suggestive of biliary origin are less frequently observed, (Fig. 10, 11).

NON-HEPATOCYTIC (CHOLANGIOLAR AND VASCULAR) MALIGNANT NEOPLASMS: These occur in the mouse liver; however, the incidence is much less than that for neoplasms of hepatocytic origin.

CHOLANGIOCARCINOMA: This lesion always occurs in conjunction with hepatocellular tumor. Prominant glandular patterns (Fig. 12) and proliferating, hyperchromatic, undifferentiated biliary epithelium forming glandular structures (Fig. 13) are observed.

HEMANGIOSARCOMA: The pale neoplasm showing irregular blood-filled spaces and numerous thrombi (Fig. 14) and a higher magnification (Fig. 15) demonstrates that large and small blood spaces are filled with spindle-shaped endothelial cells.

CONCLUSIONS

The concept of focal hyperplasia of hepatocytes exists between the categories of foci of altered cells and adenoma, and an attempt was made to define this change. None of the participants, however, were able to provide convincing examples of this lesion in the mouse liver.

The terminology and criteria suggested for use in evaluation of proliferative hepatocellular lesions in the mouse represent the current level of research and combined experiences of the participants of the workshop. The system of classification can serve as a framework to have consistency in diagnosis and interpretation of mouse liver neoplasms.

Acknowledgment

Photomicrographs were provided through the courtesy of Dr. Sidney Jones, then Director of the Division of Veterinary Pathology Armed Forces Institute of Pathology, Washington, D.C.

For the review of this manuscript, we express appreciation to: Drs. Mary Argus, Diane Beal, Richard Hill, Stephanie Irene and Daljit Sawhney of EPA, and Drs. Robert Maronport (NIEHS) and Jerrold Ward (NCI).

Particular credits are given to Dr. Diane Beal for the support in finalizing this report.

Legend

Fig 1. Focus of cellular alteration. The focus is basopilic, less than one lobule in size and may not compress surrounding tissues. H & E, x 160.

Fig 2. Focus of cellular alteration. The focus shows hepatocytes with vacuolated or rarefied cytoplasm. H & E, x 25.

Fig. 3. Focus of cellular alteration. An eosinophilic focus slightly larger than one lobule. Cells are larger than normal adjacent cells. H & E, x 65.

Fig. 4. Hepatocellular adenoma. Compression of adjacent parenchyma is present (at lower left and top-center of photomicrograph), and lobular architecture is obliterated. Basophilic hepatocytes are arranged in a trabecular pattern. H & E, x 65.

Fig. 5. Hepatocellular adenoma. Compression is distinct; lobular architecture is disrupted; and hepatocytes are pale and vacuolated. H & E, x 10.

Fig. 6. Hepatocellular adenoma consisting of a combination of eosinophilic and basophilic hepatocytes. H & E, x 10.

Fig 7. Increased magnification of hepatocellular adenoma shown in Fig. 6. Hepatocytes are eosinophilic or basophilic and show a mild degree of pleomorphism. H & E, x 160.

Fig. 8. Hepatocellular carcinoma. The carcinoma is well differentiated and has a prominent trabecular pattern that is two or more cells thick. A zone of compression can be seen at the junction of the neoplasm and the normal hepatic parenchyma. H & E, x 160.

Fig. 9. Hepatocellular carcinoma. The carcinoma is poorly differentiated and its prominent trabeculae are several cells thick. H & E, x 160.

Fig. 10. Hepatocellular carcinoma. A focus of transition between hepatocytes and irregular glandular structures resembling biliary epithelium is illustrated. H & E, x 160.

Fig. 11. Hepatocellular carcinoma. Focal change within a carcinoma suggesting transition from dark, polyhedral hepatocytes to pale, irregularly fusiform biliary epithelium. H & E, x 160.

Fig. 12. Cholangiocarcinoma. Prominent glandular growth pattern is noted at low magnification. H & E, x15.

Fig. 13. Higher magnification of cholangiocarcinoma from Fig. 12. Proliferating, hyperchromatic, and undifferentiated biliary epithelium forming glandular structures. H & E, x 160.

Fig. 14. Hemangiosarcoma. The pale neoplasm contains irregular blood-filled spaces and numerous thrombi. H & E, x 15.

Fig. 15. Higher magnification of hemangiocarcoma in Fig. 14, demonstrating large and small blood-filled spaces formed by plump, spindle-shaped endothelial cells. Hepatocytes appear trapped within the lesion. H & E, x 160.

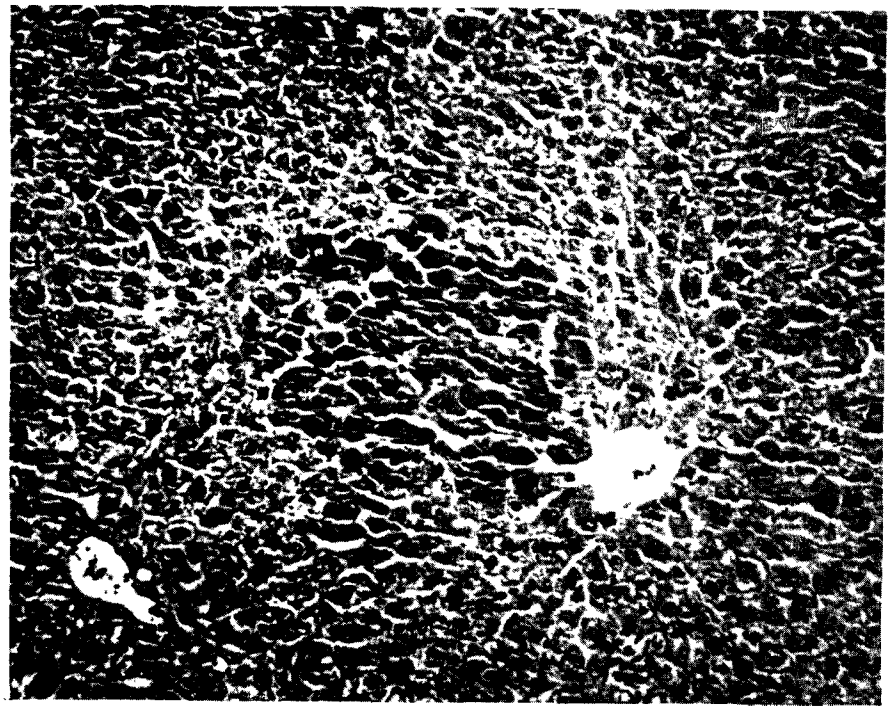

Fig. 1: Focus of cellular alteration. The focus is basophilic, less than one lobule in size and does not compress. X160.

Fig. 2: Focus of cellular alteration. The focus shows hepatocytes with vacuolated or rarefied cytoplasm. X25.

Fig. 3: Focus of cellular alteration. As eosinophilic focus slightly larger than one lobule. Cells are larger than normal adjacent cells. X65.



Fig. 4: Hepatocellular adenoma. Compression of adjacent parenchyma is present (to lower left and top-center of photomicrograph) and lobular architecture is obliterated. Basophilic hepatocytes are arranged in a trabecular pattern. X65.

Fig. 5: Hepatocellular adenoma. Compression is distinct lobular architecture is disrupted and hepatocytes are pale and vacuolated. X10.

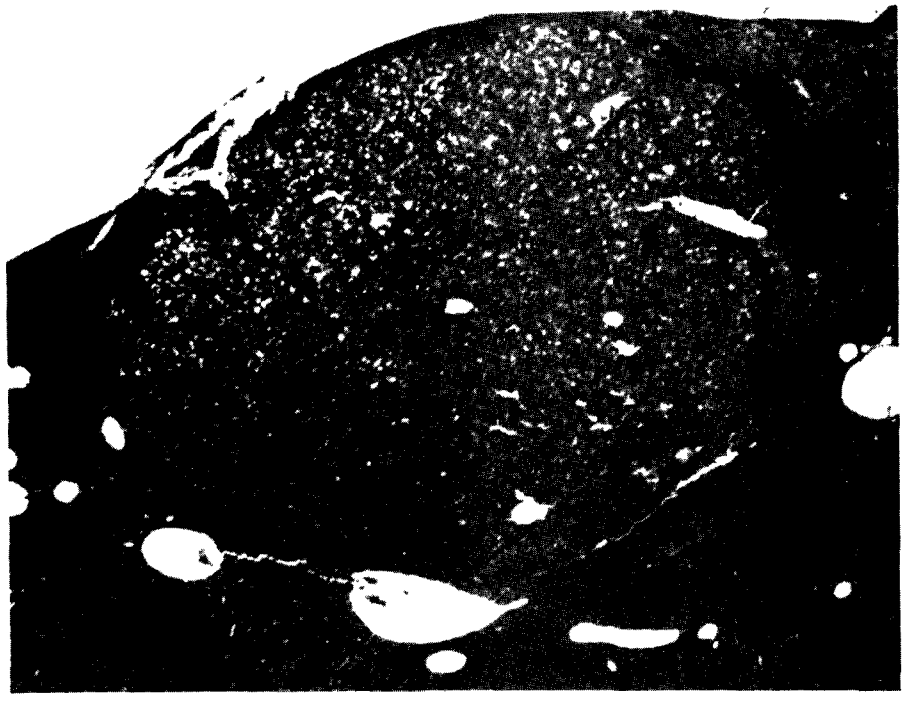

Fig. 6: Hepatocelluar adenoma consisting of a combination of eosinophilic and basophilic hepatocytes. X10.



Fig. 7: Increase magnification of hepatocellular adenoma shown in Fig 6. Hepatocytes are eosinophilic or basophilic and show a mild degree of pleomorphism. X160.

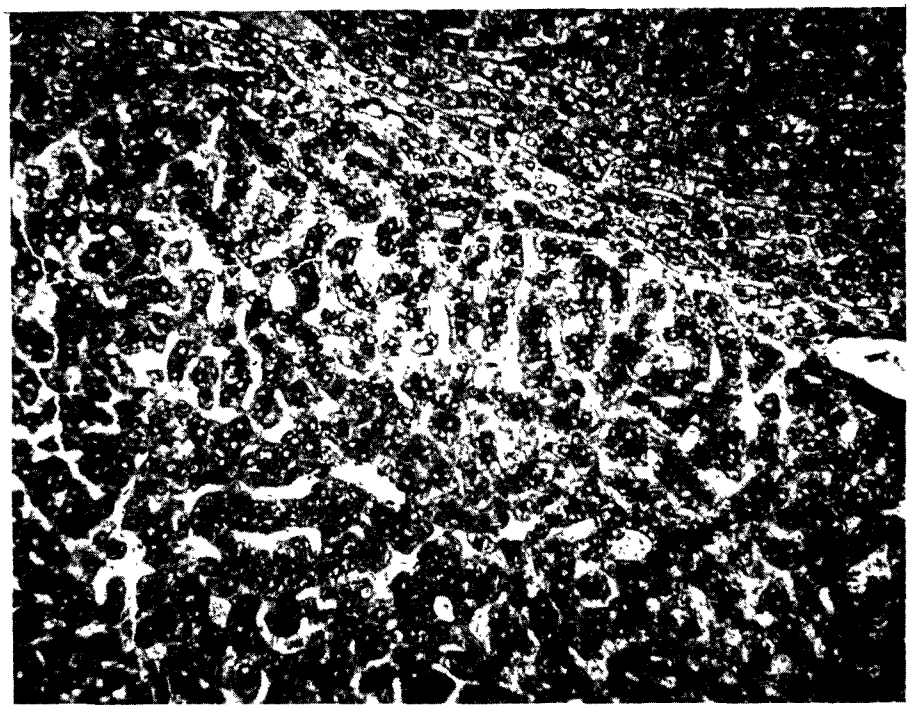

Fig. 8: Hepatocellular carcinoma. The carcinoma is well differentiated, has a prominent trabecular pattern that is 2 or more cells thick. A zone of compression can be seen at the junction of the neoplasm and the normal hepatic parenchyma. X160

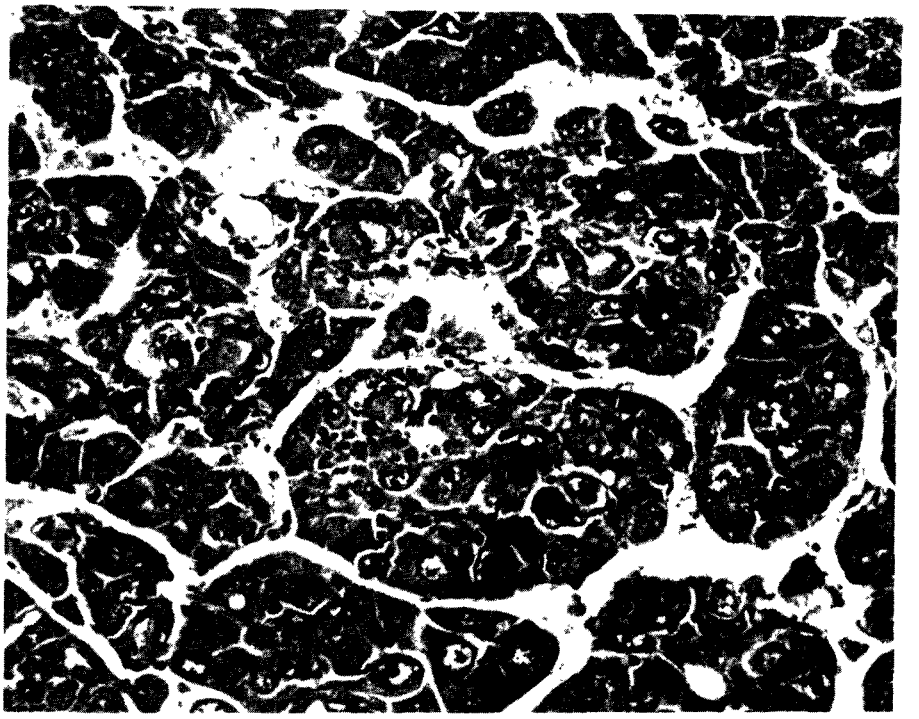

Fig. 9: Hepatocellular carcinoma. The carcinoma is poorly differentiated and its prominent trabeculae are several cells thick. X160.

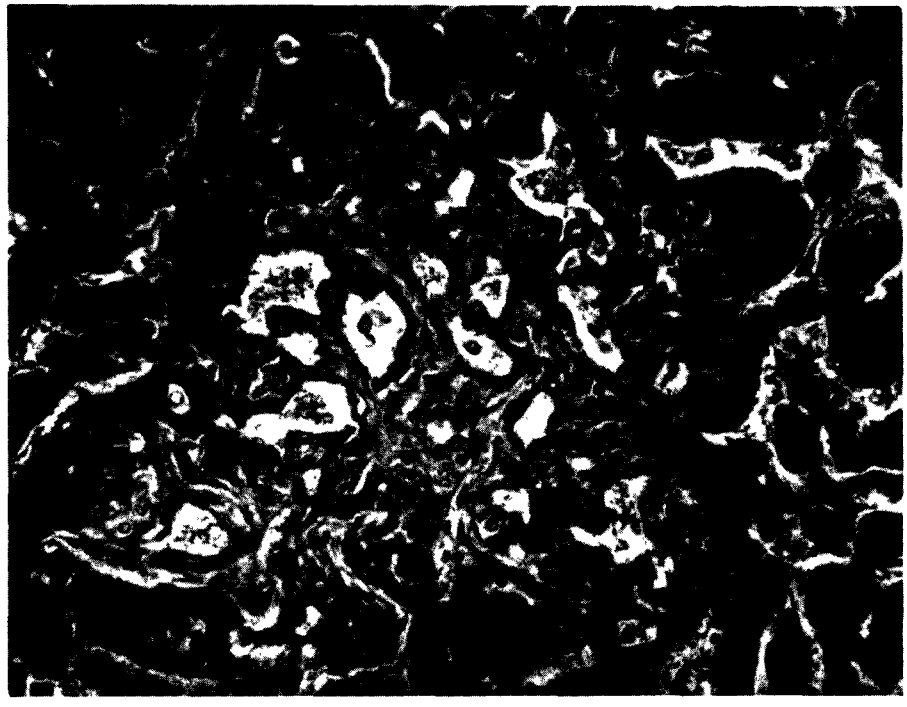

Fig. 10: Hepatocellular carcinoma. A focus of transition between hepatocytes and irregular glandular structures resembling biliary epithelium. X160.

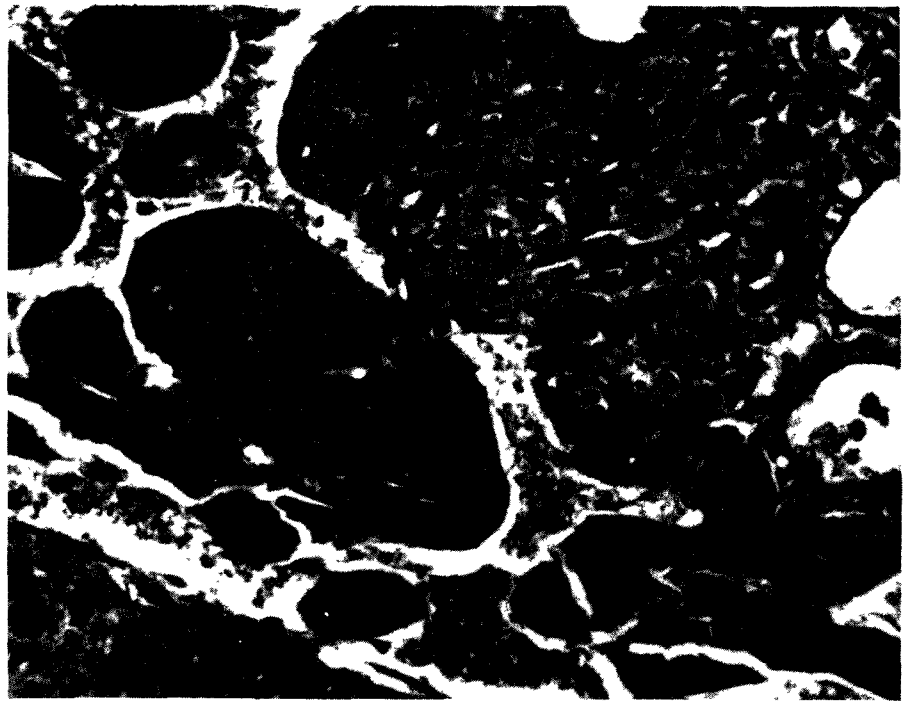

Fig. 11: Hepatocellular carcinoma. Focal change within a carcinoma suggesting tranisiton from dark, polyhedral hepatocytes to pale, irregularly fusiform biliary epithelium. X160.

Fig. 12: Cholangiocarcinoma. Prominent glandular growth pattern is noted at low magnification. X15.

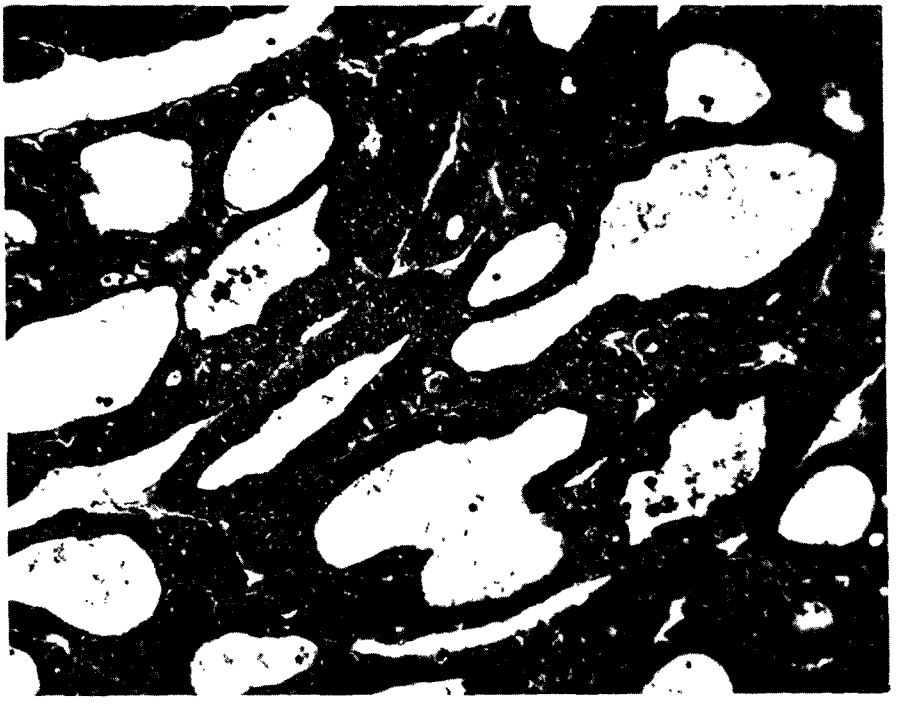

Fig. 13: Higher magnification of Fig. 12. Proliferating, hyperchromatic, undifferentiated biliary epithelium forming glandular structures. X160.

Fig. 14: Hemangiosarcoma. The pale neoplasm contains irregular blood-filled spaces and numerous thrombi. X15

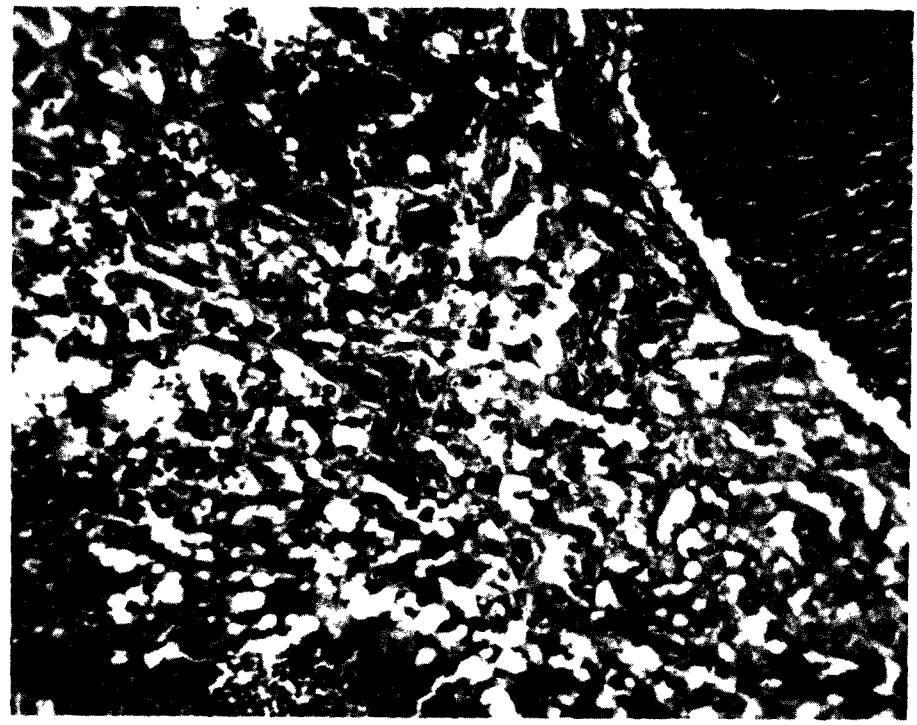

Fig. 15: Hemangiosarcoma. Higher magnification of Fig. 14, demonstrating large and small blood-filled spaces, formed by plump, spindle-shaped endothelial cells. Hepatocytes cells. Hepatocytes appear trapped within the lesion. X160